Nephrol Dial Transplant (2018) 1–13
doi: 10.1093/ndt/gfy259

ndt
Nephrology Dialysis Transplantation

REVIEW

The clinical implication of monoclonal gammopathies: monoclonal gammopathy of undetermined significance and monoclonal gammopathy of renal significance

Krzysztof Batko[1], Jolanta Malyszko[2], Artur Jurczyszyn[3], David H. Vesole[4], Morie A. Gertz[5], Xavier Leleu[6], Anna Suska[3], Marcin Krzanowski[1], Władysław Sułowicz[1], Jacek S. Malyszko[7] and Katarzyna Krzanowska[1]

[1]Departament of Nephrology, Jagiellonian University Medical College, Kraków, Poland, [2]Department of Nephrology, Dialysis and Internal Medicine, Warsaw Medical University, Warszawa, Poland, [3]Departament of Hematology, Jagiellonian University Medical College, Kraków, Poland, [4]Myeloma DIvision, John Theurer Cancer Center, Hackensack University Medical Center, Hackensack, NJ, USA, [5]Division of Hematology, Mayo Clinic, Rochester, MN, USA, [6]Service đHematologie CHU, Hopital de la Miletrie, Poitiers, France and [7]1st Department of Nephrology, Medical University, Bialystok, Poland

Correspondence and offprint requests to: Jolanta Małyszko; E-mail: jolmal@poczta.onet.pl; jmalyszko@wum.edu.pl

ABSTRACT

Monoclonal gammopathy of renal significance (MGRS) has introduced a new perspective to several well-known disease entities impacting nephrology, haematology and pathology. Given the constantly changing disease spectrum of these entities, it is clinically imperative to establish diagnostic and treatment pathways supported by evidence-based medicine. MGRS is a disease of the kidney, secondary to plasma cell clonal proliferation or immune dysfunction, requiring therapeutic intervention to eradicate the offending clone. To fully understand the disease(s), it is prerequisite to determine the significance of the findings. The diagnostic work up should be extensive due to the wide heterogeneity of clinical presentation, ultimately necessitating kidney biopsy. Particular patient profiles such as AL amyloidosis, which may be diagnosed through biopsies of other tissues/organs, may be an exception. Treatment decisions should be formulated by multidisciplinary consensus: nephrologists, haematologists and pathologists. The ultimate goal in managing MGRS is eradication of the offending plasma cell clone which requires targeted chemotherapy and, in eligible cases, haematopoietic stem cell transplantation. We present a review of diagnostic procedures, treatment options and advances in the last few years in the management of MGRS in an effort to acquaint specialists with this new face of several older diseases.

Keywords: amyloidosis, kidney function, monoclonal gammopathy of renal significance, monoclonal gammopathy of undetermined significance, multiple myeloma

DIAGNOSIS OF MONOCLONAL GAMMOPATHY OF UNDETERMINED SIGNIFICANCE

Monoclonal gammopathy of undetermined significance (MGUS) is a benign plasma cell dyscrasia first coined by Kyle [1], referring to his initial observations of an asymptomatic patient, with increased risk for plasma cell malignancy. The current diagnostic criteria define MGUS as a plasma cell dyscrasia with a serum protein electrophoresis (SPEP) 'M protein' in serum <30 g/L and bone marrow infiltration of clonal plasma cells $<10\%$, with no disease-related end-organ damage [2]. In a historical series in Olmsted County, Minnesota, the prevalence of MGUS was estimated to be 3.2% for people aged ≥ 50 and 5.3% in those aged ≥ 70 [3]. Prevalence in a US population sample of ages 10–49 was 0.34%, while estimates for persons aged ≥ 50 are 2.4%, with differences from the Minnesota population attributed to geographical variability [4, 5]. Registry investigations by Cabrera *et al.* [6], projected the world standardized incidence to be 3.76 per 100 000 residents, increasing with age. Olmsted County data estimates for annual incidence are 120 and 60 per 100 000 for males and females aged 50, increasing to 530 and 370 at age 90, respectively [7]. MGUS is conventionally managed by monitoring SPEP/urine protein electrophoresis (UPEP) scaled to risk assessment, with treatment withheld until the development of SLiM-CRAB criteria (see below).

Transformation of MGUS has a cumulative annual risk progression of 1% [8]. However, the frequency varies based on age, race and gender [3–6]. Depending on the subtype of MGUS,

Downloaded from https://academic.oup.com/ndt/advance-article/doi/10.1093/ndt/gfy259/5086133
by guest
on 29 August 2018

© The Author(s) 2018. Published by Oxford University Press on behalf of ERA-EDTA. All rights reserved.

the relative risk and nature of progression varies. For IgM MGUS, the relative risk for any progression is 10.8, most often to Waldenstrom's macroglobulinaemia, AL amyloidosis and non-Hodgkin's lymphoma. Progression for non-IgM MGUS, commonly arising from plasma cells after switch recombination, has a reported renal response (RR) of 5.7, leading to multiple myeloma (MM), plasmacytoma and AL amyloidosis, respectively [8]. Progression to an MGUS-related disorder, not accounting for death to co-morbidities, is estimated to be 10% at 10 years and 18% at 20 years [8]. MGUS risk can be stratified on three factors: abnormal serum free light chain (sFLC) ratio, M protein ≥1.5 g/dL and immunoglobulin isotype. Depending on the number of these risk factors (0–3), the projected risk of progression ranges from 7 to 55% at 20 years [8].

Analysis of the Olmsted County cohort showed a prevalence of 0.8% for light chain MGUS, with 23% of patients developing renal disease [9]. Steiner *et al.* [10] have shown that monoclonal gammopathy of renal significance (MGRS) patients are at increased risk of progression to MM than MGUS patients, with median time to progression at 18.8 years. Risk stratification is an estimate and these patients require life-long monitoring. Among 2935 MGUS patients, MGRS was detected in 1.5%, with an estimated 10% risk of progression within 1 year after diagnosis. Due to the rarity and heterogenous presentation, reliable biomarkers are exceptionally difficult to find. Perhaps a better understanding of the disease pathogenesis will allow us to discriminate high-risk patients. Recently, a prospective trial of 331 asymptomatic monoclonal gammopathy patients (MGUS = 152) analysed with clinical variables and gene expression profiles demonstrated genomic features to predict high-risk disease, suggesting the value of genomics in furthering our understanding of myelomagenesis [11]. Indeed, aside from predicting progression, identifying risk for particular lesions may aid in discovering early stages of MGRS. It is hypothesized that risk alleles for C3 glomerulopathy may require an instigating trigger such as infection or monoclonal immunoglobulin (MIg) to develop the disease [12]. Individuals with a high risk could be screened more frequently and meticulously. As of yet, identification of disease-related polymorphisms is largely limited to an experimental setting.

MM is defined as an M protein of >30 g/L or ≥10% clonal plasma cells. Patients are screened for clinical manifestations of MM under the acronym SLiM-CRAB: bone marrow plasma cells ≥60%, involved to uninvolved sFLC ratio ≥100 with absolute light chain ≥100 mg/L or >1 focal lesions on magnetic resonance imaging (MRI ≥5 mm); hypercalcaemia, renal dysfunction, anaemia and bone lesions [13]. Approximately, 14% of individuals with MM have no SLiM-CRAB criteria and are designated smoldering myeloma, an entity that is not treated outside of the context of a clinical trial [14].

MGRS DIAGNOSIS

MGRS was introduced in 2012. Leung *et al.* [2] noted that some individuals who met the criteria for MGUS may have kidney damage as a result of MIg production, or of a fragment thereof. They termed the resulting pathological entity, MGRS which was not considered to be a benign plasma cell clonal process but one that was associated with end-organ damage and required treatment [15]. Thus, the abridged definition of MGUS is the absence of renal lesions with their development warranting re-definition as MGRS.

IS MGUS EQUIVALENT TO MGRS?

MGRS encompasses an array of diseases linked to relatively benign proliferation of plasma/B cells, with subsequent excess production of MIg, or fragment thereof, or paraprotein aggregating in renal tissues. This may lead to loss of function, and ultimately renal failure. It is usually secondary to plasma cell/B-cell clonal expansion, and may result in indirect complement dysregulation [12]. In the absence of treatment, the renal damage due to deposits in tubules and glomeruli is progressive and results in irreversible damage where therapy to reverse renal dysfunction will no longer be effective [16]. Approximately, 72% of MGRS patients have progressing renal insufficiency [10]. Mortality may relate not only to an elevated risk of developing chronic kidney disease (CKD), but also to malignancy, infection or other organ dysfunction [16, 17]. In 2005–2011, the median MM survival rates were estimated at 54 months, whereas when MM was associated with moderate to severe renal impairment (RI), they were 44 and 32 months, respectively [18].

Kidney biopsy is required for the diagnosis of MGRS to include immunohistochemistry, immunofluorescence (IFE) and electron microscopy (EM) [16, 19]. Lin *et al.* [20] studied patients with monoclonal immunoglobulin deposition disease (MIDD), where 39% presented with MGUS. Findings in kidney biopsy preceded clinical diagnosis of dysproteinaemia in 68% of all cases, and ≥15% plasma cells was found only in 35%. In 28 cases of membranoproliferative glomerulonephritis (MPGN) with abnormal electrophoresis, 16 patients were classified as MGUS on the basis of bone marrow biopsy and clinical image. Renal biopsy, specifically IFE, was described by the authors as critical in initiating the evaluation for a gammopathy [21]. Serum electrophoresis may be negative, while biopsy indicates a setting of monoclonal gammopathy. Depending on the disease entity, evidence of MGRS may only consistently be found through kidney biopsy. In proliferative glomerulonephritis (PGN) with monoclonal IgG deposits (PGNMID) and non-IgG PGN, detection of a circulating MIg is reported at best at 32%, combined with a low overall yield of bone marrow examination (25%) [22]. It is hypothesized that the small size of clonal populations is beyond the detection limit of current methods, and/or they are located in extramedullary lymphoid tissue.

Finding nodular mesangial sclerosis in only 2/3 of MIDD cases highlights the need for methodical IFE analysis [23, 24]. In light chain deposition disease (LCDD) with minimal to no proteinuria, nodular sclerosis was found in only 14% of cases [25]. Although not a diagnostic criterion, it is a common characteristic in light microscopy. Furthermore, defining the subtype of MIDD requires IFE, while diagnosis is set on IFE/EM. EM is estimated to be necessary in setting a correct diagnosis in approximately 11–21% of renal lesions, while in another 21–36% it may confirm or provide additional information [26]. There are cases where the pathological protein may be hidden

Downloaded from https://academic.oup.com/ndt/advance-article-abstract/doi/10.1093/ndt/gfy259/5086133
by guest
on 29 August 2018

and requires a specific approach. In a review of 40 crystalline LCPT cases (21 patients classified to MGRS), paraffin IFE with protease digestion antigen retrieval technique was required for correct diagnosis [27]. Furthermore, in biopsy findings of C3 GN or membranoproliferative GN, paraffin immunofixation (IF) with protease digestion may unmask MIg deposits, and discover MGRS [28].

Extrarenal lesions in MGRS are not uncommon. Amyloid deposits can be limited to the vasculature, marking a different clinical profile [29]. In patients with C3 GN associated with monoclonal gammopathy, C3 deposits may coexist in renal and cutaneous vessels [30]. Perhaps better understanding of pathogenesis will allow for targeting the mechanism of tissue injury. In LCDD, extrarenal manifestations may occur in the heart and liver [31, 32]. Cardiac manifestations are reported in 1/3 of MM patients with LCDD, and are associated with shorter survival and worse treatment outcomes. It is important to note that 85% of those patients had MM while in studies where MM rates were lower [23, 24], the rate of cardiac involvement was only ∼10%. In rare cases, LCDD patients may present without proteinuria, with tubulointerstitial lesions, where nephrologists might not screen for monoclonal gammopathy [25]. Nephrologists and pathologists should closely cooperate with atypical and typical manifestations of rare diseases. In 1/3 of IgA–PGNMID patients, the initial diagnosis was IgA nephropathy, despite the presence of MIg glomerular deposits, resulting in a lack of haematological evaluation, which is crucial in MGRS [33]. Another difficulty in diagnosis may be related to membranous nephropathy with singular monoclonal IgG, which requires staining for phospholipase A2 receptor, before investigating a low-grade malignancy [34].

INVESTIGATION INTO MGRS

Presenting symptoms should be closely evaluated and documented. MGUS is more commonly seen in older individuals, as are metabolic disorders, which can mimic MGRS clinically. Unexplained RI or abnormalities such as proteinuria require extensive testing. AL amyloidosis is suspected with albuminuria (>50% in urine electrophoresis), nephrotic syndrome and relatively preserved kidney function as opposed to MIDD [35]. Cryoglobulinaemia (CG) Type I may present with hyperviscosity linked symptoms, and Type II with skin lesions and vasculitis [36]. The latter may be related to hepatitis C virus infection, in which case antiviral therapy should be promptly initiated [2]. MIDD commonly causes asymptomatic multi-organ involvement [16].

SPEP is the most basic quantitative screening test for monoclonal proteins, owing to its general availability and low cost. SPEP is positive in 81.9% of MGUS, 65.9% of AL and 55.6% of LCDD [37]. To increase sensitivity in MGRS, it should always be combined with IF and respective urine studies, UPEP and urine IF [16]. IF is purely qualitative but it allows for identification of the MIg isotype. Due to low disease burden of MGRS, a possible migration of M proteins to different fractions, and a high limit of detection in SPEP (∼500 mg/L) compared with IF (∼150 mg/dL), a negative SPEP does not exclude MGRS and should be used together IF [38]. Despite lower overall sensitivity to SPEP, the rationale for including the UPEP can be drawn from characteristic patterns, which may be indicative of a primary disease, such as high urine albumin excretion in MIDD or AL amyloidosis, or use in monitoring RI in MM [39, 40]. The additional use of antibodies targeting epitopes of sFLC detects cases missed by urine assay, though it is also true for the reverse; as such, both assays cannot be replaced [37]. Urine free light chain assays should not be utilized as there are no established normal ranges [41]. The established normal range for the kappa/lambda ratio is 0.26–1.65, whereas in patients with renal dysfunction, a range of 0.34–3.1 is considered normal [42]. It has been suggested that the lower threshold should be raised for proliferative glomerulonephritides with non-organized glomerular MIg deposition [22]. sFLC should be assessed with the knowledge that kappa monomers are more easily filtered compared with lambda dimers. Renal dysfunction, defined as an abnormal creatinine clearance (CrCl), results in elevated sFLC, though usually but not always with a maintained kappa/lambda ratio (2:1) [43]. Thus, all instances of a abnormal sFLC values should not be immediately attributed to a monoclonal gammopathy [44]. In a retrospective data review of 76 MGUS (295 observations) patients, sFLCs were observed with a >55% false-negative ratio compared with electrophoretic studies [45]. Conversly, Fulton *et al.* [46] analysed 219 cases with all urine and serum studies to a conclusion of sFLC and SPEP detecting 6% more cases than SPEP/IF and UPEP/IF. Several authors have indicated that studies criticizing IFE may use incorrect methodology, while urine studies are of equal sensitivity and may be more useful in low burden light chain clones, especially lambda dominant [47, 48]. Katzmann *et al.* [37] observed that SPEP and sFLC is the most effective basic screening panel in identifying several MGRS conditions. In LCDD 42% of patients presented with no abnormalities in SPEP/IFE, but FLCs was raised in all and matched the isotype in biopsy [25]. FLCs are not universally accepted and must be performed in combination with urine and serum studies. A cut-off value of kappa/lambda ratio >2.89 of 92% sensitivity and 97% specificity are established for plasma cell malignancy at an estimated glomerular filtration rate (eGFR) <60 mL/min/1.73 m^2; however, MGRS specific light chain values require further study [49]. In 17 MGRS patients with nephritic range proteinuria, serum and urine IF with sFLC was 100% sensitive. Although three patients with chronic glomerulonephritides were identified by sFLC and serum IF, the results do not reliably reflect the spectrum of MGRS. In PGNMID/non-IgG GN the detection rate is estimated at 32% for serum IF and sFLC [22, 50]. Another study on 19 PGNMID patients reported an overall paraprotein and clonal detection rate of 37 and 32%, respectively [51]. In the these conditions if testing for either serum IFE or sFLC is positive, bone marrow investigation with flow cytometry and immunohistochemical study may uncover a pathological clone. Determination of the best diagnostic algorithm is difficult and if there is a strong suspicion of MGRS, all five tests should be ordered. At present, there is no standard testing for the heterogenous presentation(s) of MGRS due to different disease subtypes.

Downloaded from https://academic.oup.com/ndt/advance-article-abstract/doi/10.1093/ndt/gfy259/5086133
by guest
on 29 August 2018

Without chemotherapy there is a high recurrence rate of MGRS conditions post-renal transplant, and prioritizing functional improvement requires early diagnosis as opposed to the passive monitoring in MGUS [2] (Table 3). Recent advances point to time of flight mass spectrometry (MS), without the need for expensive proteomic analysis, though the ability to discriminate and identify the pathological protein has to be demonstrated [52]. Laser microdissection and MS proteomics are recommended to confirm AL amyloidosis, cases of abnormal MIDD with truncated MIg or instances where the specific MIg region is of interest [19, 42]. Urinary exosomes, which have different characteristics in AL amyloidosis and MGUS, combined with MS may become the diagnostic and monitoring tools after more evidence is available [53]. In daily practice, parameters of kidney function, creatinine and proteinuria, can be compared with assessment of the course of progression and response to treatment [54]. However, first-line monitoring should include paraprotein levels and indirect disease activity markers, which track evolution of the primary disease.

Non-invasive screening tools for on-going diagnosis of plasma cell dyscrasia, particularly in difficult to identify MGRS conditions, are of interest. Vij *et al.* [55] reported on deep sequencing of peripheral blood, demonstrating clonal plasma cells in 96% of MM patients. In the case of IgM MGRS, which suggests the presence of B-cell/lymphoplasmacytic clone, it is necessary to attempt to specify the clonal population, through bone marrow and/or lymph node biopsy and radiographic imaging [2, 16]. F18 positron emission computed tomography can identify potential abnormal lymph nodes for biopsy, in conjunction with peripheral blood flow cytometry [54]. MRI to exclude marrow involvement may also be considered. With the heterogeneity of MGRS, aside from determining the conclusive histopathology character, exclusion of plasma cell malignancy is necessary.

TREATMENT FOR MGRS—AN OVERVIEW

A multi-disciplinary collaboration between nephrologist, pathologist and haematologist is a priority in the diagnosis and treatment of these individuals. Therapy should incorporate biopsy-driven diagnosis with particular clinical features and disease course prediction. Identification of the clone responsible for MGRS, and appropriate haematological treatment should translate into better RR, and prevention of progression. MGRS patients with doubled serum creatinine or reduced renal function may be at higher risk of haematological progression (odds ratio 2.6, CI 0.3–24) [10]. In MM, the reversal of RI has been shown to improve outcome [56]. Treatment of CD20+ clones should utilize rituximab (RTX), while MGRS conditions, particularly non-IgM MGRS, should consider MM regimens as provided below and summarized in Table 1. With the rarity and wide array of MGRS conditions, establishing strong evidence for treatment is difficult, and evidence is limited to anecdotal cases or small patient series.

CYTOTOXIC DRUGS

Historically, melphalan-prednisone (MP) was used for the treatment of plasma cell dyscrasias but due to the low response

Table 1. Therapeutic regimens for primary MGRS conditions

Drug	Character	Disease character	Severity of kidney insufficiency	Reference
Lenalidomide LoDex, MPT	Clinical trial	MM/with RI	149 patients CrCl <30 mL/min, 372 pts CrCl ≥30, <50	Dimopoulos *et al.* [57]
Bendamustine, P, V	Retrospective	MM with RI	18 eGFR <35 mL/min (11 pts eGFR 15 mL/min)	Ponisch *et al.* [58]
RTX, CYC, Dex	Retrospective	Indolent NHL	14 pts (71.5% with eGFR <60 mL/min)	Perry *et al.* [59]
POM, LoDex	Clinical trial	Glomerulonephritis related to MIg Relapsed/refractory MM with RI	Three cohorts—33 eGFR 30–45 mL/min pts, 34 < 30 mL/min eGFR pts, 14 HD pts	Dimopoulos *et al.* [60]
RTX	Clinical trial	Membranous nephropathy	eGFR ≥ 40, Proteinuria ≥ 5 g/24 h	Fervenza *et al.* [61]
VMP versus MP	Clinical trial	MM with RI	34 pts <30 mL/min GFR, 193 pts GFR 31–50 mL/min	Dimopoulos *et al.* [62]
VMPT–VT versus VMP	Clinical trial	MM with RI	33 pts <30 mL/min eGFR, 116 pts eGFR 31–50 mL/min	Morabito *et al.* [63]
Ixazomib Lenalidomide–Dex	Clinical trial	Refractory/relapsed MM	10 pts CrCl <30 mL/min, 169 pts CrCl 30–60 mL/min	Moreau *et al.* [64]
Bentamustine monotherapy/ with RTX	Retrospective	CLL/NHL	104 pts CrCl <40 mL/min	Nordstrom *et al.* [65]
V versus IMiD versus CC	Clinical trial	MM with RI	55 pts CrCl <30 mL/min (9 dialysis), 41 pts CrCl ≥30, <50 mL/min	Roussou *et al.* [66]
T-Dex	Clinical trial data	MM with RI prior to ASCT (induction therapy)	16 pts CrCl < 30 mL/min, 15 pts CrCl 30–50 mL/min (total 7 on HD)	Tosi *et al.* [67]
L-Dex	Two clinical trials	MM RI versus non-RI	16 pts CrCl <30 mL/min, CrCl ≥30 < 60 in 82 pts	Dimopoulous *et al.* [68]
POM–lowDex	Three clinical trials	MM with RI	355 pts with CrCl ≥30 and <60 mL/min (166 pts CrCl ≥30 < 45)	Siegel *et al.* [69]
Carfilzomib Dex versus Bortezomib Dex	Clinical trial	Relapsed/refractory MM	56 pts CrCl <30 mL/min, 128 pts with CrCl 30–50 mL/min	Dimopoulos *et al.* [70]

V, bortezomib; M, melphalan; L, lenalidomide; T, thalidomide-dexamethasone; V, bortezomib; CC, conventional chemotherapy; CLL, chronic lymphocytic leukaemia; NHL, non-Hodgkin lymphoma; pts, patients.

Downloaded from https://academic.oup.com/ndt/advance-article-abstract/doi/10.1093/ndt/gfy259/5086133
by guest
on 29 August 2018

rates has been replaced by more potent regimens. In LCDD with MGUS, MP and plasmapheresis prolonged survival; however, kidney function deteriorated, which marks the inefficiency of the old regimes.

To achieve a higher and more durable haematological response (HR) and potentially to qualify for kidney transplant (Ktx), high-dose melphalan supported with autologous stem cell transplantation (ASCT) is considered highly efficacious in MM and AL. SCT has been shown to improve survival in AL amyloidosis and MIDD [71, 72]. Achieving a very good partial response (VGPR)/complete response (CR) is associated with a better RR rate than a HR < VGPR [31, 32, 73]. Importantly, an advanced impairment of renal function may impact response independently of achieving HR [32, 74]. Preventing renal damage will likely only be achieved by earlier diagnosis.

IMMUNOMODULATORY AGENTS

Thalidomide, the first immunomodulatory drug (IMiD) agent approved for the treatment of myeloma, can be safely administered regardless of renal function. Outside the USA, thalidomide remains a viable choice in CrCl <50 mL/min/1. 73 m^2, since it is not renally cleared [67]. Song *et al.* [75] report that in patients with a low glomerular filtration rate (GFR), defined as <40 mL/min/1.73 m^2, cyclophosphamide (CYC) was better than MP when combined with thalidomide, with regard to renal functional improvement, adverse events, overall survival (OS) and mortality due to infection ($P < 0.001$). Lenalidomide is renally cleared and doses need to be adjusted for renal insufficiency (CrCl <60 mL/min). Complete blood counts should be performed on a regular basis in the setting of moderate to severe renal insufficiency so that the lenalidomide dose may be modified in the setting of unacceptable cytopenias [68]. In a study of 41 AL amyloidosis patients treated with lenalidomide, 66% were observed with kidney dysfunction and 10% required dialysis [76]. However, for approximately 25% of patients the initial doses were too high, and for half dosage was not appropriately adjusted. Another aspect was older age and worse renal status in those who experienced more severe impairment. Recently, a large MM trial reported that renal function-adapted lenalidomide dose resulted in similar safety across all levels of RI (Table 1) [57].

Pomalidomide (POM) is effective in lenalidomide-refractory cases, and suitable for any CrCl (Table 1). However, the recommendation for patients on dialysis is 3 mg rather than the standard 4 mg dose and should be administered following dialysis [77]. The latest results of POM and low-dose dexamethasone (LoDex) showed acceptable safety of 4 mg/day in patients with eGFR <30 mL/min/1.73 m^2 and on dialysis, though CR was only achieved in eGFR 30–45 mL/min/1.73 m^2 [60]. IMiDs have been used with effectiveness in MM, AL amyloidosis, MIDD, CG Type 1 and LCPT (Tables 1 and 2) [27, 31, 85].

PROTEASOME INHIBITORS—NOVEL DRUGS

In 2015, bortezomib, a first-generation proteasome inhibitor, was established as a class 1 A treatment (BDex) standard by the European Myeloma Network for MM with RI [86]. Bortezomib showed a favourable profile with metabolism independent of kidney function, and demonstrated to be beneficial in advanced renal failure and dialysis [87, 88]. A systematic review in 2014 concluded that bortezomib was preferable to other agents in MM with RI [89]. The most prominent adverse event is peripheral neuropathy, which may be a troublesome side effect in often mildly symptomatic MGRS conditions. Bortezomib promotes a high rate of haematological CR, as well as RR in MM with RI [90]. High-dose Dex is linked to a faster RR; however, mildly symptomatic MGRS patients may not be willing to comply with the side effects, whereas treatment-wise achieving a faster RR may improve the disease course [88]. Bortezomib high-dose Dex is recommended by the IMWG for patients with MM-related RI, whereas a three-drug scheme is deemed to improve RR [91].

In 50 patients with C3 glomerulopathy associated with monoclonal gammopathy, chemotherapy effectively achieved HR, the only predictor of RR in multivariate analysis, into significantly higher RR and renal survival rates compared with standard immunosuppression [92]. Bortezomib-based regimes made up 76% of the chemotherapy group, also being significantly associated with RR in univariate analysis. Bortezomib-based treatment in 49 patients with MIDD reported at least a VGPR in 70.4%, with HR not significantly different from HDM/SCT [93]. Maintained haematological remission was associated with survival in all patients at 85 months follow-up, in comparison with 52% at 48 months in a series published in 2003 [74]. Ziogas *et al.* [94] reported on 18 MIDD patients treated exclusively with bortezomib regimes with > VGPR in 33.3%, and an equal number progressing to end-stage renal disease (ESRD). In the 2003 study by Pozzi *et al.*, progression was similar at 36.8%, suggesting that even late induction of novel therapy will not overcome poor prognosis associated with advanced renal insufficiency. The higher efficacy reported by Cohen *et al.* may be explained by overall less advanced kidney failure and proteinuria. Together the studies demonstrate that prevention of poor kidney function is necessary to treat effectively, regardless of treatment regime.

Recently, the spectrum of MGRS has been reviewed in the context of monoclonal IgA deposits. RTX did not elicit a RR, while bortezomib-based treatment was suggested as first-line strategy [33]. Of 22 LCPT patients, six MGRS patients were treated with bortezomib-based regimes, with 33.3% reaching at least VGPR, while the remainder had stable disease [27]. Untreated patients progressed to ESRD, while multivariate analysis showed initial eGFR to be the only predictor of renal function. This brings further support to prioritizing early detection and subsequent chemotherapy to prevent deterioration of kidney function. In AL amyloidosis, CyBorD/BDex is stem cell spairing and therefore can be used in patients who may yet qualify for SCT, as well as renal failure [95]. In 53 patients with LCDD, of which 57% were in Stage 4/5 CKD, achieving at least a VGPR improved renal outcome, with bortezomib-based regimens achieving CR in eight out of nine cases [31]. MIDD has previously been reported with poor outcomes and progression to ESRD [24]. Kourelis *et al.* [73] studied 88 patients with MIDD (42% MGRS), of which 69% presented with eGFR

Downloaded from https://academic.oup.com/ndt/advance-article-abstract/doi/10.1093/ndt/gfy259/5086133
by guest
on 29 August 2018

Table 2. AL based regimens for treatment of MGRS

Drug	Patients and methods	Outcomes	Conclusions	Reference
VCD versus VD	101 pts AL amyloidosis (11 renal Stage 3)	Similar HR (P = 0.26), RR 43% for VD versus 41% for VCD (P > 0.05), similar survival (P = 0.45)	Higher dosing of Dex and CYC addition does not impact therapy outcomes significantly	Kastritis *et al.* [78]
CVD versus CTD	139 pts with AL amyloidosis	Higher CR in CVD (40.6% versus 24.6%), median PFS 28.0 versus 14.0 months, respectively	Fast clonal control did not reduce early mortality	Venner *et al.* [79]
CyBorD	230 pts with 63% with renal involvement	60% HR, 43% VGPR, 25% RR	Efficacious in patients without cardiac involvement, survival is dependent on deep response	Palladini *et al.* [80]
DARA	Retrospective review of 25 consecutive AL pts	HR in 76%, CR in 36%, VGPR 24%, well tolerated even in cardiac pts	Efficacious in heavily pre-treated	Kaufman *et al.* [81]
Pomalidomide–Dex	28 pts with AL amyloidosis	68% HR, >VGPR in 29%, 53% with response after 1 cycle	Another choice in refractory AL, improves survival, haematological progression predicts survival	Palladini *et al.* [82]
LMD	50 AL amyloidosis pts, 62% with renal load (4 in renal Stage III)	CR 18%, VGPR 32%, OR in 48%, haematologic and cardiac toxicity, 4% mortality	1 case of acute kidney injury, lenalidomide dose has to be monitored and adjusted, otherwise tolerable and efficacious	Hegenbart *et al.* [83]
M-Dex	259 AL amyloidosis pts	HR 76% CR 31% in high dose, versus 51 and 12% in attenuated	OR only in patients with HR (higher in CR versus VGPR)	Palladini *et al.* [84]

VGPHR, very good partial haematological response; EGCG, epigallocatechin gallate; LMD, lenalidomide melphalan dexamethasone; VCD, bortezomib cyclophosphamide dexamethasone; M-Dex, melphalan dexamethasone.

<30 mL/min/1.732, reporting proteasome inhibitor/SCT as the most feasible therapeutic choice. Achievement of complete/very good partial HR was necessary for a RR, while RR was an independent predictor of progression, again highlighting the principles of MGRS treatment. In patients with PGNMID who do not respond to initial treatment with RTX/CYC and steroids, bortezomib-based treatment may elicit a response [51]. Bortezomib-based therapy was effective even in refractory cases of CG Type 1 related to MM [85, 96, 97].

Carfilzomib is a second-generation proteasome inhibitor. Dimopoulos *et al.* [98] reported that carfilzomib-based therapy improved renal outcome in 55% of patients with eGFR <60 mL/min/1.73 m^2. Renal function may initially temporarily decrease, though therapy improves renal function. A cardiac risk profile should be treated with exceptional care. Patient profile assessment and further studies will determine the use in MGRS.

MONOCLONAL ANTIBODIES

Patients with MGUS treated with RTX and prednisone had improved kidney function and decreased proteinuria. In patients with MPGN secondary to indolent clones, RTX, CYC and prednisone were more effective then RTX with steroids/monotherapy [99]. Therapeutic doses of monoclonal antibodies may be administered even in renal failure and post-renal allograft settings [100, 101]. In seven patients with glomerulonephritis with monoclonal IgG deposits, RTX has been observed with promising results [five achieved CR, two partial response (PR)] [102]. The added benefit of RTX over classic chemotherapy relates to a more tolerable profile. Treatment of 14 PGNMID patients in approaches of clone-directed and empirical therapy, without identifiable discrasia was effective, with patients with no detectable clone responding with complete and PSs in all but two cases. Bortezomib-based therapy may be effective in non-responders. While empirical treatment is not easily undertaken, with clonal detection at 25–32%, it seems justified considering the rate of response [22, 51]. However, the study population is not robust and the benefit/safety of such an approach is in need of confirmation by larger studies. Interestingly, patients with eGFR ≥20 had similar rates of CR/PR to eGFR ≥45, and all patients were free of ESRD in follow-up, underscoring the value of a haematological treatment approach in MGRS [51]. RTX–CYC–Dex use in 14 patients with MIg-associated glomerulopathy secondary to indolent non-Hodgkin lymphomas was reported on, with 64% achieving CR (Table 1). The antiproteinuric effect of RTX is another beneficial aspect. A steroid-free regimen of bendamustine and RTX prospectively assessed in indolent B-cell lymphoma of renal significance resulted in 85% achieving a haematological CR and 75% a complete RR [103]. Patients without RR did not achieve HR. Bendamustine is primarily cleared by hydrolysis, with minimal kidney involvement, and recently there is substantial evidence suggesting its safety in advanced renal failure, though complete blood counts should be monitored for haematological abnormality [104, 105] (Table 1). RTX should be considered in patients with IgM-associated MGRS, especially when

Downloaded from https://academic.oup.com/ndt/advance-article-abstract/doi/10.1093/ndt/gfy259/5086133
by guest
on 29 August 2018

Table 3. Monoclonal gammopathy in the setting of kidney transplantation

Patients and methods	Outcomes	Conclusions	Reference
27 LCPT patients treated with chemotherapy (11 SCT), 9 with no treatment	Lowest mortality, best HRs in SCT, though patients were younger, and had best initial and final renal function	Best renal outcome compared with chemotherapy or no treatment, SCT stabilized or improved renal function	Stokes *et al.* [27]
64 MIDD patients, 16 pts treated with SCT, 4 Ktx	3 recurrences in 4 Ktx patients, range of 7–43 months, 38% progression to ESRD in SCT	High creatinine at biopsy is associated with poor outcome, chemotherapy after recurrence is inefficient	Nasr *et al.* [24]
49 MIDD patients, 3 Ktx with 1 VGPR and 2 CR, 18 SCT	No recurrences in 3 Ktx patients, allograft rejection in 1 patient after 3 years, SCT was safe and tolerated but patients were younger, bortezomib-based treatment had similar RR rates	Sustained ≥VGPR necessary for Ktx, SCT is preferred CKD stages	Cohen *et al.* [93]
29 MPGN Ktx patients, 6 with monoclonal protein (4 MGUS, 1 CLL)	23% of MPGN patients have monoclonal proteins, may increase risk of recurrence, SCT resolved recurrence, plasmapheres as passive maintenance	MPGN patients should be screened for monoclonal proteins	Lorenz *et al.* [110]
6 LCDD with SCT	1 patient did not survive SCT, all others achieved HR, 2 relapses with 1 improved by subsequent chemotherapy	Insufficient response to SCT may be an indication for Ktx in select patients after achieving HR	Lorenz *et al.* [122]
7 LCDD Ktx patients	Median recurrence 2–45 months for 5 patients, subsequent 4 deaths, only 1 patient free of renewal	A HR must be achieved before attempting Ktx	Leung *et al.* [109]
2 PGNMID Ktx patients (1 de novo, 1 recurrent)	Improvement in graft function and serum creatinine in 2 year follow-up	RTX can be effective in both recurrent and de novo PGNMID pts	Merhi *et al.* [123]
3 PGNMID (2 CLL)	Despite RTX treatment there was 1 progression to ESRD and one malignancy progression	RTX therapy may improve renal outcomes in short term	Barbour *et al.* [124]
53 LCDD, 7 Ktx, 16 SCT	2 recurrences in patients without prior chemotherapy, 1 rejection of Ktx, 3 patients in CR in >6.8 year follow-up, 1 SCT-related death, 13/15 achieved CR	SCT can be successful even in CKD Stage 4; however, renal survival is still worse, SCT appears more safe than in AL amyloidosis	Sayed *et al.* [31]
21 Ktx wit C3GN	66.7% recurrence, of which 21% associated with monoclonal gammopathy, recurrence earlier (3.6 month median versus 43.3 month), more progressive course (P = NS), SCT improved kidney function in one patient, stable graft in 10-year follow-up	Monoclonal gammopathy patients are at risk of an earlier and more aggressive disease	Zand *et al.* [125]
548 Ktx patients	Prevalence 8.1%, 5.2 year median to MGUS discovery, higher rate of MBL, history of inflammatory kidney disease as predictive factor, no association with age and gender, no impact on graft survival, overall survival, incidence of malignancy	MGUS pre- and post-transplant may be different conditions in terms of management, however, strict follow-up is needed, especially in MBL patients	Alfano *et al.* [126]
1, 593 Ktx recipients	3% pre-transplant MG ($n = 34$)	No cases of progression, no association with malignancy incidence or mortality	Jimenez Zepeda *et al.* [117]
587 Ktx recipients	2.9% incidence (9 pts pre-transplant, 8 post)	No progression during 6-year follow-up, MGUS not a contraindication to Ktx	Bancu *et al.* [127]
3, 518 Ktx recipients	42 patients (23 pre-transplant, 19 post), median survival 26.1 versus 28.0 years respectively, 4 haematological malignancies developed in pre, 2 PTLD >15 years post-transplant	Diagnosis of PTLD was symptom-based, true incidence may be higher, exclusion of associated kidney disease and malignancy is necessary before Ktx	Naina *et al.* [118]

MBL, monoclonal B-cell lymphocytosis.

Downloaded from https://academic.oup.com/ndt/article-abstract/doi/10.1093/ndt/gfy259/5086133
by guest
on 29 August 2018

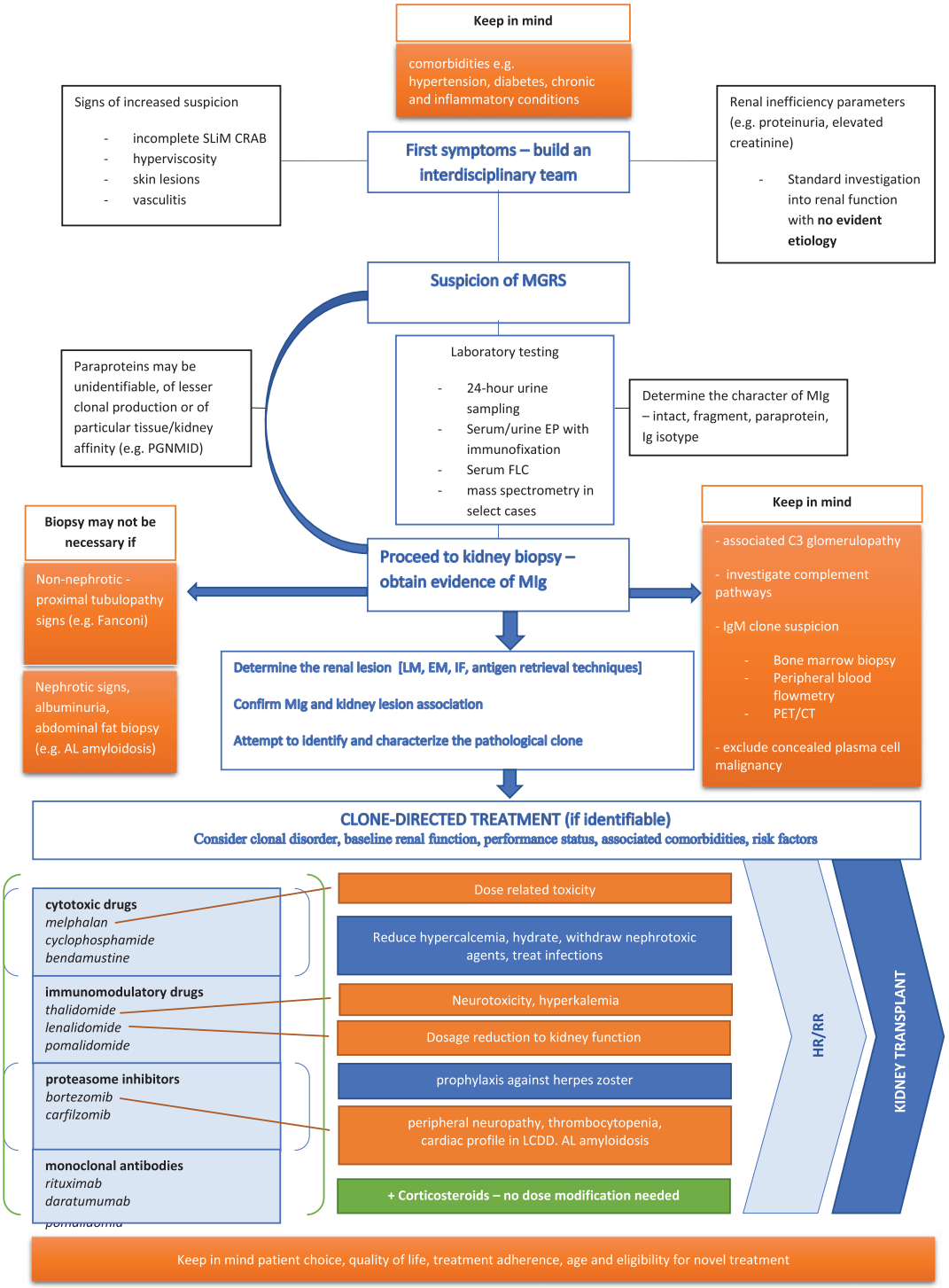

FIGURE 1: Diagnostic and therapeutic algorithm of monoclonal gammopathy of renal significance.

CD20+ cells can be identified, while non-IgM-associated diseases more often require MM-like treatment.

Recently an anti CD38 monoclonal antibody, daratumumab (DARA), has been approved for the treatment of newly diagnosed and relapsed MM patients [106]. Like many Phase 3 registration trials, the study excluded patients with CrCl $\leq$20 mL/min. Anecdotal evidence of safety and reduction of dialysis frequency in a patient with DARA monotherapy has recently been reported [107]. A case of PGNMID refractory to RTX and bortezomib was successfully treated with DARA [108]. Due to independence of kidney clearance and positive results in RI, it may prove beneficial in MGRS. There is an on-going Phase 2 study of DARA in MGRS [NCT03095118].

MGRS, TRANSPLANT AND ESRD

Renal transplant in MGRS is controversial as frequent recurrences are observed when the abnormal clone is not adequately

Downloaded from https://academic.oup.com/ndt/advance-article-abstract/doi/10.1093/ndt/gfy259/5086133
by guest
on 29 August 2018

suppressed [24, 109, 110]. The current treatment paradigm in MGRS is to achieve a complete HR as a means of improving post-transplant outcome and preventing recurrence [71, 72, 111]. Cibeira *et al.* [112] report that in 340 AL amyloidosis patients subject to SCT, 43% attained CR improving long-term OS and organ response (OR). In recent years, the treatment-related mortality (TRM) has decreased from 13.8% between 1994 and 2003 to 5.6% between 2004 and 2008. In part this probably reflects the experience of established centres; however, with access to novel agents, there are other options for treatment. Cardiac involvement should be screened for in LCDD due to a high TRM (23%) with SCT, as opposed to non-cardiac patients [32]. PS does not indicate treatment failure and significantly increases survival compared with patients lacking response [113].

A study in AL amyloidosis patients associated the need for dialysis within 30 days of SCT with highest early death risk and TRM. Patients with both eGFR <40 mL/min/1.73 m^2 and serum albumin <2.5 mg/dL had a 43.8 and 28.1% risk of requiring dialysis and chance of TRM, respectively. Identifying and screening for such risk factors should improve the feasibility of SCT in MGRS conditions [114]. In a study of 36 patients with AL amyloidosis/MIDD who were dialysis dependent for ESRD, CR was reached in 53% at 1 year post SCT, with an 8% TRM [72]. Achievement of dialysis independence was possible in patients receiving a Ktx after successful SCT. Similarly, a study in MM with RI found no impact on survival for patients who were dialysis dependent [115]. Further research is required to evaluate risk factors and establish whether select ESRD patients may benefit from SCT.

Literature reports are conflicting on the approach to Ktx in MGUS [116–118]. Bansal *et al.* [119] reflect that a select group of plasma dyscrasia patients should be considered for Ktx, especially those subject to dialysis-associated complications. In AL and MIDD, patients achieving haematological CR have been reported with successful Ktx [120, 121]. Monoclonal gammopathy in the setting of Ktxs is presented in Table 3. In summary, primary disease activity, organ function and patient performance should dictate selection for Ktx. We propose an algorithm for diagnostic and therapeutic treatment of MGRS (Figure 1).

CONCLUSION

With under-recognition of the wide spectrum of MGRS, accurate classification, evidence-based therapy and expert established management is required. Renal involvement in MGRS results from the direct deposition of monoclonal protein and its light- or heavy-chain fragments in the kidney. IFE microscopy is essential to identify the offending monoclonal protein and its renal tissue distribution. In selected cases, MS is of value. MGRS therapy is directed to eliminate the clonal plasma cell or B-cell population. Adverse events particular to the chosen drug should complement the patient profile. Early detection, diagnosis and chemotherapy may improve kidney function. It should be stressed that both the renal pathology and the underlying haematological disorders influence the management and prognosis of MGRS. Upon achieving HR, ASCT and Ktx should be considered as therapy endpoints in MGRS.

CONFLICT OF INTEREST STATEMENT

None declared.

REFERENCES

1. Kyle RA. Monoclonal gammopathy of undetermined significance. *Natural History in 241 Cases. Am J Med [Internet]* 1978; [cited 2017 Oct 24] 64: 814–826 Available from: http://www.ncbi.nlm.nih.gov/pubmed/645746
2. Leung N, Bridoux F, Hutchison CA *et al.* Monoclonal gammopathy of renal significance: when MGUS is no longer undetermined or insignificant. *Blood [Internet]* 2012; [cited 2017 Oct 24] 120: 4292–4295 Available from: http://www.ncbi.nlm.nih.gov/pubmed/23047823
3. Kyle RA, Therneau TM, Rajkumar SV *et al.* Prevalence of monoclonal gammopathy of undetermined significance. *N Engl J Med [Internet]* 2006; [cited 2017 Oct 24] 354: 1362–1369 Available from: http://www.ncbi.nlm.nih.gov/pubmed/16571879
4. Landgren O, Graubard BI, Kumar S *et al.* Prevalence of myeloma precursor state monoclonal gammopathy of undetermined significance in 12372 individuals 10–49 years old: a population-based study from the National Health and Nutrition Examination Survey. *Blood Cancer J* 2017; 7: e618 [cited 2018 Feb 9] 7. Available from. http://www.ncbi.nlm.nih.gov/pubmed/29053158
5. Landgren O, Graubard BI, Katzmann JA *et al.* Racial disparities in the prevalence of monoclonal gammopathies: a population-based study of 12 482 persons from the National Health and Nutritional Examination Survey. *Leukemia [Internet]* 2014; 28: 1537–1542 [cited 2018 Jun 22] Available from: http://www.ncbi.nlm.nih.gov/pubmed/24441287
6. Cabrera Q, Macro M, Hebert B *et al.* Epidemiology of monoclonal gammopathy of undetermined significance (MGUS): the experience from the specialized registry of hematologic malignancies of Basse-Normandie (France). *Cancer Epidemiol [Internet]* 2014; 38: 354–356 [cited 2017 Oct 24] Available from: http://www.ncbi.nlm.nih.gov/pubmed/24880205
7. Therneau TM, Kyle RA, Melton LJ *et al.* Incidence of monoclonal gammopathy of undetermined significance and estimation of duration before first clinical recognition. *Mayo Clin Proc [Internet]* 2012; [cited 2017 Dec 23] 87: 1071–1079 Available from: http://www.ncbi.nlm.nih.gov/pubmed/22883742
8. Kyle RA, Larson DR, Therneau TM *et al.* Long-term follow-up of monoclonal gammopathy of undetermined significance. *N Engl J Med* 2018; [cited 2018 Apr 23] 378: 241–249 Available from: http://www.ncbi.nlm.nih.gov/pubmed/29342381
9. Dispenzieri A, Katzmann JA, Kyle RA *et al.* Prevalence and risk of progression of light-chain monoclonal gammopathy of undetermined significance: a retrospective population-based cohort study. *Lancet [Internet]* 2010; [cited 2018 Feb 9] 375: 1721–1728 Available from: http://www.ncbi.nlm.nih.gov/pubmed/20472173
10. Steiner N, Göbel G, Suchecki P *et al.* Monoclonal gammopathy of renal significance (MGRS) increases the risk for progression to multiple myeloma: an observational study of 2935 MGUS patients. *Oncotarget [Internet]* 2018; [cited 2018 Apr 27] 9: 2344–2356 Available from: http://www.ncbi.nlm.nih.gov/pubmed/29416776
11. Dhodapkar MV, Sexton R, Waheed S *et al.* Clinical, genomic, and imaging predictors of myeloma progression from asymptomatic monoclonal gammopathies (SWOG S0120). *Blood [Internet]* 2014; [cited 2018 Jun 22] 123: 78–85 Available from: http://www.ncbi.nlm.nih.gov/pubmed/24144643
12. Zand L, Kattah A, Fervenza FC *et al.* C3 glomerulonephritis associated with monoclonal gammopathy: a case series. *Am J Kidney Dis [Internet]* 2013; [cited 2017 Dec 29] 62: 506–514 Available from: http://www.ncbi.nlm.nih.gov/pubmed/23623956
13. Rajkumar SV, Dimopoulos MA, Palumbo A *et al.* International Myeloma Working Group updated criteria for the diagnosis of multiple myeloma. *Lancet Oncol [Internet]* 2014; [cited 2018 Jun 23] 15: e538–e548 Available from: http://linkinghub.elsevier.com/retrieve/pii/S1470204514704425

Downloaded from https://academic.oup.com/ndt/advance-article-abstract/doi/10.1093/ndt/gfy259/5086133
by guest
on 29 August 2018

14. Ravindran A, Bartley AC, Holton SJ *et al*. Prevalence, incidence and survival of smoldering multiple myeloma in the United States. *Nat Publishing Group [Internet]* 2016; 6: 2018–2023 [cited Jun] Available from: https://www.ncbi.nlm.nih.gov/pmc/articles/PMC5098258/pdf/bcj2016100a.pdf
15. Fermand J-P, Bridoux F, Kyle RA *et al*. How I treat monoclonal gammopathy of renal significance (MGRS). *Blood [Internet]* 2013; [cited 2017 Oct 27] 122: 3583–3590 Available from: http://www.ncbi.nlm.nih.gov/pubmed/24108460
16. Bridoux F, Leung N, Hutchison CA *et al*. Diagnosis of monoclonal gammopathy of renal significance. *Kidney Int [Internet]* 2015; [cited 2017 Oct 24] 87: 698–711 Available from: http://www.ncbi.nlm.nih.gov/pubmed/25607108
17. Kristinsson SY, Björkholm M, Andersson TM-L *et al*. Patterns of survival and causes of death following a diagnosis of monoclonal gammopathy of undetermined significance: a population-based study. *Haematologica [Internet]* 2009; [cited 2018 Feb] 94: 1714–1720 Available from: http://www.ncbi.nlm.nih.gov/pubmed/19608666
18. Dimopoulos MA, Delimpasi S, Katodritou E *et al*. Significant improvement in the survival of patients with multiple myeloma presenting with severe renal impairment after the introduction of novel agents. *Ann Oncol [Internet]* 2014; [cited 2018 Apr 23] 25: 195–200 Available from: https://academic.oup.com/annonc/article-lookup/doi/10.1093/annonc/mdt483
19. Correia SO, Santos S, Malheiro J *et al*. Monoclonal gammopathy of renal significance: diagnostic workup. *WJN* 2017; [cited 2017 Oct 27] 6: 72–78 Available from: http://www.ncbi.nlm.nih.gov/pubmed/28316940
20. Lin J, Markowitz GS, Valeri AM *et al*. Renal monoclonal immunoglobulin deposition disease: the disease spectrum. *J Am Soc Nephrol [Internet]* 2001; [cited 2018 Jun 23] 12: 1482–1492 Available from: http://www.ncbi.nlm.nih.gov/pubmed/11423577
21. Sethi S, Zand L, Leung N *et al*. Membranoproliferative glomerulonephritis secondary to monoclonal gammopathy. *Clin J Am Soc Nephrol [Internet]* 2010; [cited 2017 Dec 8] 5: 770–782 Available from: http://www.ncbi.nlm.nih.gov/pubmed/20185597
22. Bhutani G, Nasr SH, Said SM *et al*. Hematologic characteristics of proliferative glomerulonephritides with nonorganized monoclonal immunoglobulin deposits. *Mayo Clin Proc [Internet]* 2015; [cited 2018 Jun 23] 90: 587–596 Available from: http://www.ncbi.nlm.nih.gov/pubmed/25939936
23. Cohen C, El-Karoui K, Alyanakian M-A *et al*. Light and heavy chain deposition disease associated with CH1 deletion. *Clin Kidney J [Internet]* 2015; [cited 2017 Oct 26] 8: 237–239 Available from: http://www.ncbi.nlm.nih.gov/pubmed/25815184
24. Nasr SH, Valeri AM, Cornell LD *et al*. Renal monoclonal immunoglobulin deposition disease: a report of 64 patients from a single institution. *Clin J Am Soc Nephrol [Internet]* 2012; [cited 2018; Feb 9] 7: 231–239 Available from: http://www.ncbi.nlm.nih.gov/pubmed/22156754
25. Sicard A, Karras A, Goujon J-M *et al*. Light chain deposition disease without glomerular proteinuria: a diagnostic challenge for the nephrologist. *Nephrol Dial Transplant [Internet]* 2014; [cited 2018 Jul 7] 29: 1894–1902 Available from: http://www.ncbi.nlm.nih.gov/pubmed/24619059
26. Haas M. A reevaluation of routine electron microscopy in the examination of native renal biopsies. *J Am Soc Nephrol [Internet]* 1997; 8: 70–76 Available from: http://www.ncbi.nlm.nih.gov/pubmed/9013450
27. Stokes MB, Valeri AM, Herlitz L *et al*. Light chain proximal tubulopathy: clinical and pathologic characteristics in the modern treatment era. *J Am Soc Nephrol [Internet]* 2016; [cited 2018 Jun 23] 27: 1555–1565 Available from: http://www.ncbi.nlm.nih.gov/pubmed/26374607
28. Larsen CP, Messias NC, Walker PD *et al*. Membranoproliferative glomerulonephritis with masked monotypic immunoglobulin deposits. *Kidney Int [Internet]* 2015; [cited 2018 Feb 10] 88: 867–873 Available from: http://www.ncbi.nlm.nih.gov/pubmed/26154922
29. Eirin A, Irazabal MV, Gertz MA *et al*. Clinical features of patients with immunoglobulin light chain amyloidosis (AL) with vascular-limited deposition in the kidney. *Nephrol Dial Transplant [Internet]* 2012; [cited 2018 Feb 10] 27: 1097–1101 Available from: http://www.ncbi.nlm.nih.gov/pubmed/22067518
30. Alonso-Titos J, Perea-Ortega L, Sola E *et al*. C3 glomerulonephritis associated with monoclonal gammopathy of renal significance: case report. *BMC Nephrol* 2018; Jul 6] 19: 129 Available from: http://www.ncbi.nlm.nih.gov/pubmed/29884135
31. Sayed RH, Wechalekar AD, Gilbertson JA *et al*. Natural history and outcome of light chain deposition disease. *Blood [Internet]* 2015; [cited 2017 Dec 8] 126: 2805–2810 Available from: http://www.ncbi.nlm.nih.gov/pubmed/26392598
32. Mohan M, Buros A, Mathur P *et al*. Clinical characteristics and prognostic factors in multiple myeloma patients with light chain deposition disease. *Am J Hematol* 2017; [cited 2018 Jul 7] 92: 739–745 Available from: http://www.ncbi.nlm.nih.gov/pubmed/28383130
33. Vignon M, Cohen C, Faguer S *et al*. The clinicopathologic characteristics of kidney diseases related to monotypic IgA deposits. *Kidney Int [Internet]* 2017; [cited 2018 Jul] 91: 720–728 Available from: http://www.ncbi.nlm.nih.gov/pubmed/28069266
34. Best Rocha A, Larsen CP. Membranous glomerulopathy with light chain-restricted deposits: a clinicopathological analysis of 28 cases. *Kidney Int Rep [Internet]* 2017; [cited 2018 Jul 6] 2: 1141–1148 Available from: http://www.ncbi.nlm.nih.gov/pubmed/29270522
35. Nasr SH, Valeri AM, Sethi S *et al*. Clinicopathologic correlations in multiple myeloma: a case series of 190 patients with kidney biopsies. *Am J Kidney Dis [Internet]* 2012; [cited 2017 Oct 26] 59: 786–794 Available from: http://www.ncbi.nlm.nih.gov/pubmed/22417785
36. Glavey SV, Leung N. Monoclonal gammopathy: the good, the bad and the ugly. *Blood Rev [Internet]* 2016; [cited 2017 Dec 24] 30: 223–231 Available from: http://www.sciencedirect.com/science/article/pii/S0268960X15000946#bb0130
37. Katzmann JA, Kyle RA, Benson J *et al*. Screening panels for detection of monoclonal gammopathies. *Clin Chem [Internet]* 2009; [cited 2017 Oct 25] 55: 1517–1522 Available from: http://www.ncbi.nlm.nih.gov/pubmed/19520758
38. Yadav P, Leung N, Sanders PW *et al*. The use of immunoglobulin light chain assays in the diagnosis of paraprotein-related kidney disease. *Kidney Int [Internet]* 2015; [cited 2018 Feb 9] 87: 692–697 Available from: http://www.ncbi.nlm.nih.gov/pubmed/25296094
39. Sugihara H, Chihara D, Seike K *et al*. Percentage of urinary albumin excretion and serum-free light-chain reduction are important determinants of renal response in myeloma patients with moderate to severe renal impairment. *Blood Cancer J [Internet]* 2014; [cited 2018 Jun 24] 4: e235 Available from: http://www.ncbi.nlm.nih.gov/pubmed/25083819
40. Leung N, Gertz M, Kyle RA *et al*. Urinary albumin excretion patterns of patients with cast nephropathy and other monoclonal gammopathy-related kidney diseases. *Clin J Am Soc Nephrol [Internet]* 2012; [cited 2018 Jun 24] 7: 1964–1968 Available from: http://www.ncbi.nlm.nih.gov/pubmed/23024162
41. Ciocchini M, Arbelbide J, Musso CG. Monoclonal gammopathy of renal significance (MGRS): the characteristics and significance of a new meta-entity. *Int Urol Nephrol [Internet]* 2017; [cited 2017 Oct 26]: 49: 2171–2175 Available from: http://www.ncbi.nlm.nih.gov/pubmed/28425076
42. Sethi S, Rajkumar SV, D'Agati VD. The complexity and heterogeneity of monoclonal immunoglobulin–associated renal diseases. *J Am Soc Nephrol* 2018; 29: 1810–1823.
43. Hutchison CA, Harding S, Hewins P *et al*. Quantitative assessment of serum and urinary polyclonal free light chains in patients with chronic kidney disease. *Clin J Am Soc Nephrol [Internet]* 2008; [cited 2017 Dec 25] 3: 1684–1690 Available from: http://www.ncbi.nlm.nih.gov/pubmed/18945993
44. Jurczyszyn A, Ochrem B. Abnormal serum free light chain ratio does not always indicate monoclonal gammopathy. *Polskie Archiwum Medycyny Wewnetrznej [Internet]* 2015; [cited 2017 Dec 29] 125: 502–504 Available from: http://www.ncbi.nlm.nih.gov/pubmed/26266682
45. Singh G. Serum free light chain assay and κ/λ ratio: performance in patients with monoclonal gammopathy-high false negative rate for κ/λ ratio. *J Clin Med Res* 2017; [cited 2018 Jun 25] 9: 46–57 Available from: http://www.ncbi.nlm.nih.gov/pubmed/27924175
46. Fulton RB, Fernando SL. Serum free light chain assay reduces the need for serum and urine immunofixation electrophoresis in the evaluation of monoclonal gammopathy. *Ann Clin Biochem [Internet]* 2009; [cited 2018 Jun 25] 46: 407–412 Available from: http://www.ncbi.nlm.nih.gov/pubmed/19641008

Downloaded from https://academic.oup.com/ndt/advance-article-abstract/doi/10.1093/ndt/gfy259/5086133
by guest
on 29 August 2018

47. Levinson SS. Urine immunofixation electrophoresis remains important and is complementary to serum free light chain. *Clin Chem Lab Med [Internet]* 2011; [cited 2018 Jun 25] 49: 1801–1804 Available from: http://www.ncbi.nlm.nih.gov/pubmed/21663562 [CrossRef][Mismatch]
48. Lee WS, Singh G. Serum free light chains in neoplastic monoclonal gammopathies: relative under-detection of lambda dominant Kappa/Lambda ratio, and underproduction of free lambda light chains, as compared to kappa light chains, in patients with neoplastic monoclonal gammopathies. *J Clin Med Res* 2018; [cited 2018 Jun 25] 10: 562–569 Available from: http://www.ncbi.nlm.nih.gov/pubmed/29904440
49. Xu B, Tang Y, Zhou J *et al*. Disease spectrum of abnormal serum free light chain ratio and its diagnostic significance. *Oncotarget [Internet]* 2017; [cited 2017 Dec 29] 8: 82268–82279 Available from: http://www.ncbi.nlm.nih.gov/pubmed/29137262
50. Koo EH, Shin J, Jang HR *et al*. Diagnostic performances of M-protein tests according to the clinical presentations of kidney disease. *Eur J Intern Med [Internet]* 2016; [cited 2018 Feb 9] 33: 88–92 Available from: http://www.ncbi.nlm.nih.gov/pubmed/27421913
51. Gumber R, Cohen JB, Palmer MB *et al*. A clone-directed approach may improve diagnosis and treatment of proliferative glomerulonephritis with monoclonal immunoglobulin deposits. *Kidney Int [Internet]* 2018; 94: 199–205 Available from: https://doi.org/10.1016/j.kint.2018.02.020
52. Leung N, Barnidge DR, Hutchison CA. Laboratory testing in monoclonal gammopathy of renal significance (MGRS). *Clin Chem Lab Med [Internet]* 2016; [cited 2017 Oct 25] 54: 929–937 Available from: http://www.ncbi.nlm.nih.gov/pubmed/27107835 [CrossRef][Mismatch]
53. Ramirez-Alvarado M, Ward CJ, Huang BQ *et al*. Differences in immunoglobulin light chain species found in urinary exosomes in light chain amyloidosis (AL). *PLoS ONE [Internet]* 2012; [cited 2018 Jul 7] 7: e38061 Available from: http://www.ncbi.nlm.nih.gov/pubmed/22723846
54. Hogan JJ, Weiss BM. Bridging the divide: an onco-nephrologic approach to the monoclonal gammopathies of renal significance. *Clin J Am Soc Nephrol [Internet]* 2016; [cited 2017 Oct 26] 11: 1681–1691 Available from: http://www.ncbi.nlm.nih.gov/pubmed/27416775
55. Vij R, Mazumder A, Klinger M *et al*. Deep sequencing reveals myeloma cells in peripheral blood in majority of multiple myeloma patients. *Clin Lymphoma Myeloma Leuk [Internet]* 2014; [cited 2017 Oct 25] 14: 131–139.e1 Available from: http://www.ncbi.nlm.nih.gov/pubmed/24629890
56. Gonsalves WI, Leung N, Rajkumar SV *et al*. Improvement in renal function and its impact on survival in patients with newly diagnosed multiple myeloma. *Blood Cancer J* 2015; [cited 2018 Feb 3] 5: e296 Available from: http://www.nature.com/doifinder/10.1038/bcj.2015.20
57. Dimopoulos MA, Cheung MC, Roussel M *et al*. Impact of renal impairment on outcomes with lenalidomide and dexamethasone treatment in the FIRST trial, a randomized, open-label phase 3 trial in transplant-ineligible patients with multiple myeloma. *Haematologica [Internet]* 2016; [cited 2018 Jul 7] 101: 363–370 Available from: http://www.ncbi.nlm.nih.gov/pubmed/26659916
58. Pönisch W, Andrea M, Wagner I *et al*. Successful treatment of patients with newly diagnosed/untreated multiple myeloma and advanced renal failure using bortezomib in combination with bendamustine and prednisone. *J Cancer Res Clin Oncol* 2012; [cited 2018 Jul 2] 138: 1405–1412 Available from: http://www.ncbi.nlm.nih.gov/pubmed/22526157
59. Perry M, Delarche A, Ribes D *et al*. Rituximab-cyclophosphamide-dexamethasone is highly effective in patients with monoclonal Ig deposit-related glomerulopathy and indolent non-Hodgkin lymphomas. *Am J Hematol* 2014; [cited 2018 Jul 1] 89: 969–973 Available from: http://doi.wiley.com/10.1002/ajh.23798
60. Dimopoulos M, Weisel K, van de Donk Nwcj *et al*. Pomalidomide plus low-dose dexamethasone in patients with relapsed/refractory multiple myeloma and renal impairment: results from a Phase II trial. *J Clin Oncol* 2018; 36: 2035–2043.
61. Fervenza FC, Canetta PA, Barbour SJ *et al*. A multicenter randomized controlled trial of rituximab versus cyclosporine in the treatment of idiopathic membranous nephropathy (MENTOR). *Nephron [Internet]* 2015; [cited 2017 Dec 25] 130: 159–168 Available from: http://www.ncbi.nlm.nih.gov/pubmed/26087670
62. Dimopoulos MA, Richardson PG, Schlag R *et al*. VMP (bortezomib, melphalan, and prednisone) is active and well tolerated in newly diagnosed patients with multiple myeloma with moderately impaired renal function, and results in reversal of renal impairment: cohort analysis of the Phase III VISTA study. *JCO* 2009; [cited 2017 Dec 8] 27: 6086–6093 Available from: http://www.ncbi.nlm.nih.gov/pubmed/19858394
63. Morabito F, Gentile M, Mazzone C *et al*. Safety and efficacy of bortezomib-melphalan-prednisone-thalidomide followed by bortezomib-thalidomide maintenance (VMPT-VT) versus bortezomib-melphalan-prednisone (VMP) in untreated multiple myeloma patients with renal impairment. *Blood [Internet]* 2011; [cited 2017 Dec 9] 118: 5759–5766 Available from: http://www.ncbi.nlm.nih.gov/pubmed/21951682
64. Moreau P, Masszi T, Grzasko N *et al*. Oral ixazomib, lenalidomide, and dexamethasone for multiple myeloma. *N Engl J Med* 2016; [cited 2018 Apr 27] 374: 1621–1634 Available from: http://www.nejm.org/doi/10.1056/NEJMoa1516282
65. Nordstrom BL, Knopf KB, Teltsch DY *et al*. The safety of bendamustine in patients with chronic lymphocytic leukemia or non-Hodgkin lymphoma and concomitant renal impairment: a retrospective electronic medical record database analysis. *Leuk Lymphoma [Internet]* 2014; [cited 2017 Dec 13] 55: 1266–1273 Available from: http://www.ncbi.nlm.nih.gov/pubmed/23987821
66. Roussou M, Kastritis E, Christoulas D *et al*. Reversibility of renal failure in newly diagnosed patients with multiple myeloma and the role of novel agents. *Leuk Res [Internet]* 2010; [cited 2017 Dec 15] 34: 1395–1397 Available from: http://www.ncbi.nlm.nih.gov/pubmed/20510452
67. Tosi P, Zamagni E, Tacchetti P *et al*. Thalidomide-dexamethasone as induction therapy before autologous stem cell transplantation in patients with newly diagnosed multiple myeloma and renal insufficiency. *Biol Blood Marrow Transplant [Internet]* 2010; [cited 2018 Apr 27] 16: 1115–1121 Available from: http://www.ncbi.nlm.nih.gov/pubmed/20197100
68. Dimopoulos M, Alegre A, Stadtmauer EA *et al*. The efficacy and safety of lenalidomide plus dexamethasone in relapsed and/or refractory multiple myeloma patients with impaired renal function. *Cancer [Internet]* 2010; 116: 3807 [cited 2017 Dec 15] Available from: http://www.ncbi.nlm.nih.gov/pubmed/20564094
69. Siegel DS, Weisel KC, Dimopoulos MA *et al*. Pomalidomide plus low-dose dexamethasone in patients with relapsed/refractory multiple myeloma and moderate renal impairment: a pooled analysis of three clinical trials. *Leuk Lymphoma [Internet]* 2016; [cited 2017 Dec 15] 57: 2833–2838 Available from: http://www.ncbi.nlm.nih.gov/pubmed/27267105
70. Dimopoulos MA, Goldschmidt H, Niesvizky R *et al*. Carfilzomib or bortezomib in relapsed or refractory multiple myeloma (ENDEAVOR): an interim overall survival analysis of an open-label, randomised, phase 3 trial. *Lancet Oncol [Internet]* 2017; [cited 2017 Dec 6] 18: 1327–1337 Available from: http://www.ncbi.nlm.nih.gov/pubmed/28843768
71. Telio D, Shepherd J, Forrest D *et al*. High-dose melphalan followed by auto-SCT has favorable safety and efficacy in selected patients with light chain deposition disease and light and heavy chain deposition disease. *Bone Marrow Transplant* 2012; [cited 2017 Dec 8] 47: 453–455 Available from: http://www.nature.com/doifinder/10.1038/bmt.2011.87
72. Batalini F, Econimo L, Quillen K *et al*. High-dose melphalan and stem cell transplantation in patients on dialysis due to immunoglobulin light-chain amyloidosis and monoclonal immunoglobulin deposition disease. *Biol Blood Marrow Transplant [Internet]* 2018; [cited 2017 Dec 25] 24: 127–132 Available from: http://www.ncbi.nlm.nih.gov/pubmed/28865972
73. Kourelis TV, Nasr SH, Dispenzieri A *et al*. Outcomes of patients with renal monoclonal immunoglobulin deposition disease. *Am J Hematol* 2016; [cited 2018 Jul 2] 91: 1123–1128 Available from: http://www.ncbi.nlm.nih.gov/pubmed/27501122
74. Pozzi C, D'Amico M, Fogazzi GB *et al*. Light chain deposition disease with renal involvement: clinical characteristics and prognostic factors. *Am J Kidney Dis [Internet]* 2003; [cited 2018 Jun 23] 42: 1154–1163 Available from: http://www.ncbi.nlm.nih.gov/pubmed/14655186
75. Song M-K, Chung J-S, Shin H-J *et al*. Cyclophosphamide-containing regimen (TCD) is superior to melphalan-containing regimen (MPT) in elderly multiple myeloma patients with renal impairment. *Ann Hematol*

Downloaded from https://academic.oup.com/ndt/advance-article-abstract/doi/10.1093/ndt/gfy259/5086133
by guest
on 29 August 2018

[Internet] 2012; [cited 2017 Dec 9] 91: 889–896 Available from: http://www.ncbi.nlm.nih.gov/pubmed/22237937
76. Specter R, Sanchorawala V, Seldin DC *et al*. Kidney dysfunction during lenalidomide treatment for AL amyloidosis. *Nephrol Dial Transplant [Internet]* 2011; [cited 2018 Jul 7] 26: 881–886 Available from: http://www.ncbi.nlm.nih.gov/pubmed/20693160
77. Li Y, Wang X, O'Mara E *et al*. Population pharmacokinetics of pomalidomide in patients with relapsed or refractory multiple myeloma with various degrees of impaired renal function. *CPAA* 2017; [cited 2018 Feb 4] 9: 133–145 Available from: http://www.ncbi.nlm.nih.gov/pubmed/29184451
78. Kastritis E, Gavriatopoulou M, Roussou M *et al*. Addition of cyclophosphamide and higher doses of dexamethasone do not improve outcomes of patients with AL amyloidosis treated with bortezomib. *Blood Cancer J* 2017; [cited 2017 Dec 15] 7: e570 Available from: http://www.ncbi.nlm.nih.gov/pubmed/28622303
79. Venner CP, Gillmore JD, Sachchithanantham S *et al*. A matched comparison of cyclophosphamide, bortezomib and dexamethasone (CVD) versus risk-adapted cyclophosphamide, thalidomide and dexamethasone (CTD) in AL amyloidosis. *Leukemia [Internet]* 2014; [cited 2018 Jul 5] 28: 2304–2310 Available from: http://www.ncbi.nlm.nih.gov/pubmed/25027514
80. Palladini G, Sachchithanantham S, Milani P *et al*. A European collaborative study of cyclophosphamide, bortezomib, and dexamethasone in upfront treatment of systemic AL amyloidosis. *Blood [Internet]* 2015; [cited 2017 Dec 9] 126: 612–615 Available from: http://www.ncbi.nlm.nih.gov/pubmed/25987656
81. Kopel T, Kaufman JS, Hamburg N *et al*. Endothelium-dependent and -independent vascular function in advanced chronic kidney disease. *CJASN* 2017; [cited 2018 Apr 18] 12: 1588–1594 Available from: http://cjasn.asnjournals.org/lookup/doi/10.2215/CJN.12811216
82. Palladini G, Milani P, Foli A *et al*. A Phase 2 trial of pomalidomide and dexamethasone rescue treatment in patients with AL amyloidosis. *Blood [Internet]* 2017; [cited 2018 Apr 26] 129: 2120–2123 Available from: http://www.ncbi.nlm.nih.gov/pubmed/28130212
83. Hegenbart U, Bochtler T, Benner A *et al*. Lenalidomide/melphalan/dexamethasone in newly diagnosed patients with immunoglobulin light chain amyloidosis: results of a prospective phase 2 study with long-term follow up. *Haematologica [Internet]* 2017; [cited 2017 Dec 26] 102: 1424–1431 Available from: http://www.ncbi.nlm.nih.gov/pubmed/28522573
84. Palladini G, Milani P, Foli A *et al*. Oral melphalan and dexamethasone grants extended survival with minimal toxicity in AL amyloidosis: long-term results of a risk-adapted approach. *Haematologica [Internet]* 2014; [cited 2017 Dec 15] 99: 743–750 Available from: http://www.ncbi.nlm.nih.gov/pubmed/24213149
85. Payet J, Livartowski J, Kavian N *et al*. Type I cryoglobulinemia in multiple myeloma, a rare entity: analysis of clinical and biological characteristics of seven cases and review of the literature. *Leuk Lymphoma [Internet]* 2013; 54: 767–777 Available from: http://www.tandfonline.com/doi/full/10.3109/10428194.2012.671481
86. Terpos E, Kleber M, Engelhardt M *et al*. European Myeloma Network guidelines for the management of multiple myeloma-related complications. *Haematologica [Internet]* 2015; [cited 2017 Dec 4] 100: 1254–1266 Available from: http://www.ncbi.nlm.nih.gov/pubmed/26432383
87. Chanan-Khan AA, Kaufman JL, Mehta J *et al*. Activity and safety of bortezomib in multiple myeloma patients with advanced renal failure: a multicenter retrospective study. *Blood [Internet]* 2007; [cited 2018 Jul 2] 109: 2604–2606 Available from: http://www.ncbi.nlm.nih.gov/pubmed/17138816
88. Dimopoulos MA, Roussou M, Gkotzamanidou M *et al*. The role of novel agents on the reversibility of renal impairment in newly diagnosed symptomatic patients with multiple myeloma. *Leukemia* 2013; 27: 423–429
89. Kouroukis TC, Baldassarre FG, Haynes AE *et al*. Bortezomib in multiple myeloma: systematic review and clinical considerations. *Curr Oncol (Toronto, Ont.) [Internet]* 2014; [cited 2017 Dec 4] 21: e573–e603 Available from: http://www.ncbi.nlm.nih.gov/pubmed/25089109
90. Zhu W, Chen W. Bortezomib-based treatment for multiple myeloma patients with renal impairment: a systematic review and meta-analysis of observational studies. *Medicine [Internet]* 2016; 95: e5202 Available from: http://www.ncbi.nlm.nih.gov/pmc/articles/PMC5120900/
91. Dimopoulos MA, Terpos E, Chanan-Khan A *et al*. Renal impairment in patients with multiple myeloma: a consensus statement on behalf of the International Myeloma Working Group. *JCO* 2010; 28: 4976–4984
92. Chauvet S, Frémeaux-Bacchi V, Petitprez F *et al*. Treatment of B-cell disorder improves renal outcome of patients with monoclonal gammopathy–associated C3 glomerulopathy. *Blood [Internet]* 2017; [cited 2017 Oct 26] 129: 1437–1447 Available from: http://www.ncbi.nlm.nih.gov/pubmed/28069603
93. Cohen C, Royer B, Javaugue V *et al*. Bortezomib produces high hematological response rates with prolonged renal survival in monoclonal immunoglobulin deposition disease. *Kidney Int [Internet]* 2015; [cited 2017 Dec 25] 88: 1135–1143 Available from: http://www.ncbi.nlm.nih.gov/pubmed/26176826
94. Ziogas DC, Kastritis E, Terpos E *et al*. Hematologic and renal improvement of monoclonal immunoglobulin deposition disease after treatment with bortezomib-based regimens. *Leuk Lymphoma [Internet]* 2017; [cited 2017 Dec 25] 58: 1832–1839 Available from: http://www.ncbi.nlm.nih.gov/pubmed/27967286
95. Milani P, Merlini G, Palladini G. Novel therapies in light chain amyloidosis. *Kidney Int Rep [Internet]* 2018; [cited 2018 Jul 4] 3: 530–541 Available from: http://www.ncbi.nlm.nih.gov/pubmed/29854961
96. Spizzo G, Mitterer M, Gunsilius E. Bortezomib for the treatment of refractory Type-1 cryoglobulinaemia. *Br J Haematol [Internet]* 2010; [cited 2018 Jul 7] 150: 235–237 Available from: http://doi.wiley.com/10.1111/j.1365-2141.2010.08184.x
97. Talamo G, Claxton D, Tricot G *et al*. Response to bortezomib in refractory Type I cryoglobulinemia. *Am J Hematol* 2008; [cited 2018 Jul 7] 83: 883–884 Available from: http://www.ncbi.nlm.nih.gov/pubmed/18756542
98. Dimopoulos MA, Roussou M, Gavriatopoulou M *et al*. Cardiac and renal complications of carfilzomib in patients with multiple myeloma. *Blood Adv* 2017; [cited 2017 Dec 6] 1: 449–454 Available from: http://www.bloodadvances.org/lookup/doi/10.1182/bloodadvances.2016003269
99. Strati P, Nasr SH, Leung N *et al*. Renal complications in chronic lymphocytic leukemia and monoclonal B-cell lymphocytosis: the Mayo Clinic experience. *Haematologica [Internet]* 2015; [cited 2018 Jul 3] 100: 1180–1188 Available from: http://www.ncbi.nlm.nih.gov/pubmed/26088927
100. Salama AD, Pusey CD. Drug insight: rituximab in renal disease and transplantation. *Nat Clin Pract Nephrol [Internet]* 2006; [cited 2017 Dec 8] 2: 221–230 Available from: http://www.nature.com/doifinder/10.1038/ncpneph0133
101. Jillella AP, Dainer PM, Kallab AM *et al*. Treatment of a patient with end-stage renal disease with rituximab: pharmacokinetic evaluation suggests rituximab is not eliminated by hemodialysis. *Am J Hematol* 2002; [cited 2018 Jul] 71: 219–222 Available from: http://www.ncbi.nlm.nih.gov/pubmed/12410580
102. Guiard E, Karras A, Plaisier E *et al*. Patterns of noncryoglobulinemic glomerulonephritis with monoclonal Ig deposits: correlation with IgG subclass and response to rituximab. *Clin J Am Soc Nephrol* 2011; 6: 1609–1616
103. Ribes D, Hachem HEL, Oberic L *et al*. Bendamustine plus rituximab for indolent B-cell lymphoma of renal significance. *Am J Hematol* 2018; 93: 356–362
104. Darwish M, Bond M, Hellriegel E *et al*. Pharmacokinetic and pharmacodynamic profile of bendamustine and its metabolites. *Cancer Chemother Pharmacol* 2015; [cited 2017 Dec 15] 75: 1143–1154 Available from: http://www.ncbi.nlm.nih.gov/pubmed/25829094
105. Pönisch W, Moll B, Bourgeois M *et al*. Bendamustine and prednisone in combination with bortezomib (BPV) in the treatment of patients with relapsed or refractory multiple myeloma and light chain-induced renal failure. *J Cancer Res Clin Oncol [Internet]* 2013; [cited 2018 Jul 2] 139: 1937–1946 Available from: http://www.ncbi.nlm.nih.gov/pubmed/24046251
106. Mateos M-V, Dimopoulos MA, Cavo M *et al*. Daratumumab plus bortezomib, melphalan, and prednisone for untreated myeloma. *N Engl J Med* 2018; 378: 518–528.
107. Rocchi S, Tacchetti P, Pantani L *et al*. Safety and efficacy of daratumumab in dialysis-dependent renal failure secondary to multiple myeloma. *Haematologica [Internet]* 2018; [cited 2018 Jul 2] 103: e277–e278 Available from: http://www.ncbi.nlm.nih.gov/pubmed/29622654

Downloaded from https://academic.oup.com/ndt/advance-article-abstract/doi/10.1093/ndt/gfy259/5086133
by guest
on 29 August 2018

108. Anand, S Miller, D Chipman, G Morris, D, Srinivas S. Daratumumab for severe refractory proliferative glomerulonephritis with monoclonal immune deposits (PGNMID). *ATC Abstr [Internet]* 2017; [cited 2018 Jul 3] Available from: https://atcmeetingabstracts.com/abstract/daratumumab-for-severe-refractory-proliferative-glomerulonephritis-with-monoclonal-immune-deposits-pgnmid/
109. Leung N, Lager DJ, Gertz MA *et al*. Long-term outcome of renal transplantation in light-chain deposition disease. *Am J Kidney Dis [Internet]* 2004; [cited 2018 Feb 9] 43: 147–153 Available from: http://www.ncbi.nlm.nih.gov/pubmed/14712438
110. Lorenz EC, Sethi S, Leung N *et al*. Recurrent membranoproliferative glomerulonephritis after kidney transplantation. *Kidney Int [Internet]* 2010; [cited 2018 Feb 9] 77: 721–728 Available from: http://www.ncbi.nlm.nih.gov/pubmed/20130531
111. Leung N, Nasr SH. A patient with abnormal kidney function and a monoclonal light chain in the urine. *Clin J Am Soc Nephrol* 2016; 11: 1073–1082
112. Cibeira MT, Sanchorawala V, Seldin DC *et al*. Outcome of AL amyloidosis after high-dose melphalan and autologous stem cell transplantation: long-term results in a series of 421 patients. *Blood [Internet]* 2011; [cited 2018 Feb 3] 118: 4346–4352 Available from: http://www.ncbi.nlm.nih.gov/pubmed/21828140
113. Gertz MA, Lacy MQ, Dispenzieri A *et al*. Autologous stem cell transplant for immunoglobulin light chain amyloidosis: a status report. *Leuk Lymphoma [Internet]* 2010; [cited 2018 Feb 3] 51: 2181–2187 Available from: http://www.ncbi.nlm.nih.gov/pubmed/20958232
114. Leung N, Kumar SK, Glavey SV *et al*. The impact of dialysis on the survival of patients with immunoglobulin light chain (AL) amyloidosis undergoing autologous stem cell transplantation. *Nephrol Dial Transplant* 2016; [cited 2018 Jul 7] 31: 1284–1289 Available from: https://academic.oup.com/ndt/article-lookup/doi/10.1093/ndt/gfv328
115. Badros A, Barlogie B, Siegel E *et al*. Results of autologous stem cell transplant in multiple myeloma patients with renal failure. *Br J Haematol* 2001; [cited 2018 Jul 7] 114: 822–829 Available from: http://www.ncbi.nlm.nih.gov/pubmed/11564069
116. Soltero L, Carbajal H, Xu J *et al*. Initial survival data of kidney transplant patients with pre-transplant monoclonal gammopathy. *Clin Transplant [Internet]* 2012; [cited 2018 Feb 3] 26: 300–304 Available from: http://www.ncbi.nlm.nih.gov/pubmed/22044717
117. Jimenez-Zepeda VH, Heilman RL, Engel RA *et al*. Monoclonal gammopathy of undetermined significance does not affect outcomes in patients undergoing solid organ transplants. *Transplantation [Internet]* 2011; [cited 2018 Feb 3] 92: 570–574 Available from: http://www.ncbi.nlm.nih.gov/pubmed/21712755
118. Naina HVK, Harris S, Dispenzieri A *et al*. Long-term follow-up of patients with monoclonal gammopathy of undetermined significance after kidney transplantation. *Am J Nephrol* 2012; [cited 2018 Feb] 35: 365–371 Available from: http://www.ncbi.nlm.nih.gov/pubmed/22473253
119. Bansal T, Garg A, Snowden JA *et al*. Defining the role of renal transplantation in the modern management of multiple myeloma and other plasma cell dyscrasias. *Nephron Clin Pract [Internet]* 2012; [cited 2018 Feb 3] 120: c228 www.karger.com
120. Hassoun H, Flombaum C, D'Agati VD *et al*. High-dose melphalan and auto-SCT in patients with monoclonal Ig deposition disease. *Bone Marrow Transplant* 2008; [cited 2018 Feb 3] 42: 405–412 Available from: http://www.ncbi.nlm.nih.gov/pubmed/18574442
121. Herrmann SMS, Gertz MA, Stegall MD *et al*. Long-term outcomes of patients with light chain amyloidosis (AL) after renal transplantation with or without stem cell transplantation. *Nephrol Dial Transplant [Internet]* 2011; [cited 2018 Feb 3] 26: 2032–2036 Available from: http://www.ncbi.nlm.nih.gov/pubmed/21543655
122. Lorenz EC, Gertz MA, Fervenza FC *et al*. Long-term outcome of autologous stem cell transplantation in light chain deposition disease. *Nephrol Dial Transplant [Internet]* 2008; [cited 2018 Jul 5] 23: 2052–2057 Available from: http://www.ncbi.nlm.nih.gov/pubmed/18178602
123. Merhi B, Patel N, Bayliss G *et al*. Proliferative glomerulonephritis with monoclonal IgG deposits in two kidney allografts successfully treated with rituximab. *Clin Kidney J [Internet]* 2017; [cited 2018 Feb 10] 10: 405–410 Available from: https://academic.oup.com/ckj/article-lookup/doi/10.1093/ckj/sfx001
124. Barbour SJ, Beaulieu MC, Zalunardo NY *et al*. Proliferative glomerulonephritis with monoclonal IgG deposits secondary to chronic lymphocytic leukemia. Report of two cases. *Nephrol Dial Transplant [Internet]* 2011; [cited 2018 Feb 10] 26: 2712–2714 Available from: https://academic.oup.com/ndt/article-lookup/doi/10.1093/ndt/gfr251
125. Zand L, Lorenz EC, Cosio FG *et al*. Clinical findings, pathology, and outcomes of C3GN after kidney transplantation. *J Am Soc Nephrol [Internet]* 2014; [cited 2018 Jul 5] 25: 1110–1117 Available from: http://www.ncbi.nlm.nih.gov/pubmed/24357668
126. Alfano G, Fontana F, Colaci E *et al*. Monoclonal gammopathy of undetermined significance after kidney transplantation. *Transplantation [Internet]* 2017; [cited 2017 Oct 24] 101: e337–e342 Available from: http://www.ncbi.nlm.nih.gov/pubmed/28731904
127. Bancu I, Cañas L, Juega FJ *et al*. Outcomes of monoclonal gammopathy of undetermined significance in patients who underwent kidney transplantation. *Transplant Proc [Internet]* 2015; [cited 2018 Feb 10] 47: 2344–2345 Available from: http://www.ncbi.nlm.nih.gov/pubmed/26518922

Received: 26.3.2018; Editorial decision: 14.7.2018

Downloaded from https://academic.oup.com/ndt/article-abstract/doi/10.1093/ndt/gfy259/5086133
by guest
on 29 August 2018